

Use Of Minne Ties Under Local In The ER For Bilateral Mandible Fractures

A healthy 26 year old woman presented to the emergency department after a bicycle accident in which she sustained an incomplete left parasymphiseal mandible fracture and a right mildly displaced mandibular ramus fracture (figures 1 and 2.) In addition to this, she had fractured her left central maxillary incisor, but otherwise had excellent dentition.

The patient was given the option of proceeding to the operating room to have formal arch bars or hybrid arch bars placed versus having Minne Ties placed under local anesthesia in the ER. She elected to proceed with placement under local. She had a fairly high degree of anxiety and was given IV versed and dilaudid by the ER physicians. 4% viscous lidocaine was placed on cotton and was put into four quadrants of the gingivobuccal sulcus for several minutes. 2% lidocaine with 1:100,000 epinephrine was also injected into the interdental papillae where each Minne Tie was planned. Four 1.0mm Minne Ties were used on the left and right and were placed with minimal difficulty and minimal patient discomfort. The ties were placed between the first/second molar, first molar and second premolar, first/second premolar and canine/first premolar. The ties were not tightened until the patient was placed into maximal intercuspation and closed reduction was achieved.

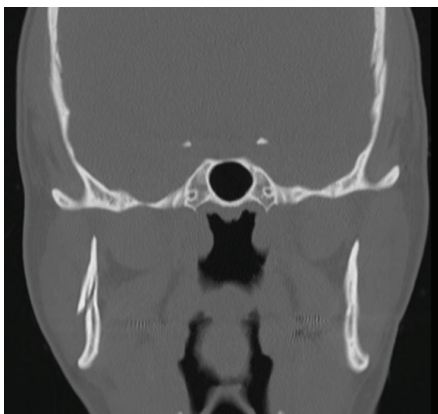


Figure 1. Pre-operative right mandibular ramus fracture with mild displacement.

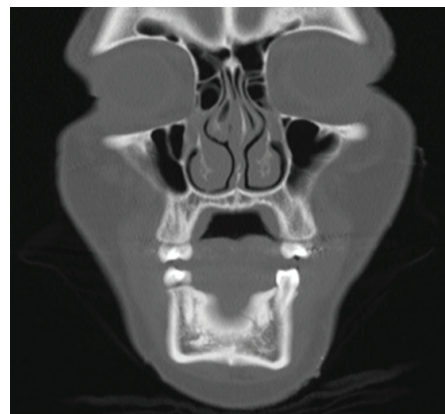
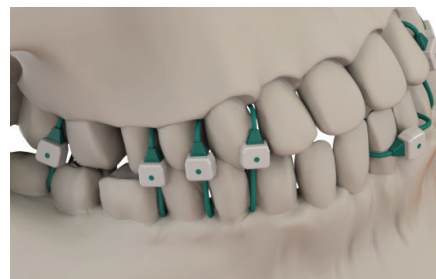

Figure 2. Pre-operative left mandibular non-displaced parasymphysis fracture



Minne Ties dental occlusion ties

She was left in the maxillomandibular fixation with Minne Ties for a total of two weeks and returned for follow-up. The ties did not loosen and she tolerated them very well. She reported that she hadn't taken any Tylenol or NSAIDs at all for the second week post-treatment. She reported mild dental pain and no jaw pain.

Her occlusion was subjectively similar to her pre-morbid condition. The ties were removed in the office with scissors and needle drivers after placing cotton soaked with 4% viscous lidocaine in four quadrants of the gingivobuccal sulcus for several minutes. No injection with local was required. She rated discomfort and difficulty of removal of the Minne Ties as a 1/10. She also denied any pain or discomfort of her buccal mucosa or lip mucosa associated with the Minne Ties. Her maximal interincisal opening was reduced as expected after being in MMF for 2 weeks, but was 1.5cm. Overall, this was felt to be an excellent treatment by the patient and from a treating physician's perspective.



David Montag, MD, MS
Otolaryngologist –
Head and Neck Surgeon
Hennepin County Medical Center
David.Montag@hcmcd.org